

This resource was organised and funded by AbbVie.
It has been developed in collaboration with Claire Harris,
Susan Gurden, Dr Jane Martindale, Claire Jeffries and NASS.

For UK healthcare professionals only

Assessing the Signs, Symptoms, and Clinical Manifestations of Axial SpA

Enhance your patient examination skills

Claire Harris, Senior Physiotherapist,
London North West University Healthcare NHS Trust

Susan Gurden, Advanced Physiotherapy
Practitioner in Rheumatology,
Aneurin Bevan Health Board, Wales

Dr Jane Martindale, Clinical Specialist Physiotherapist,
Wrightington, Wigan and Leigh NHS Foundation Trust

Claire Jeffries, Physiotherapy Clinical Specialist
in Hydrotherapy and Rheumatology,
Solent NHS Trust, Portsmouth

Contents

<u>Introduction</u>	<u>3</u>
<u>Module objectives</u>	<u>3</u>
<u>What is axial SpA?</u>	<u>4</u>
<u>The ASAS features of axial SpA</u>	<u>5</u>
<u>Clinical features of axial SpA</u>	<u>6</u>
<u>Laboratory features of axial SpA</u>	<u>12</u>
<u>Imaging</u>	<u>13</u>
<u>Axial SpA co-morbidities</u>	<u>16</u>
<u>Assess your knowledge of the clinical features of axial SpA</u>	<u>18</u>
<u>Glossary</u>	<u>22</u>
<u>Appendix</u>	<u>23</u>
<u>Useful contacts and further information</u>	<u>24</u>
<u>Modules in this series</u>	<u>24</u>

Introduction

This module provides a detailed look at the clinical features, plus laboratory and imaging findings, of axial spondyloarthritis (axSpA), as defined by the Assessment of SpondyloArthritis international Society (ASAS)* criteria, and rationales for their use. Being able to identify the features of axial SpA during patient assessments will help to determine if onward referral to a rheumatologist is required.

This module supports module 2 of this series, 'What is Axial Spondyloarthritis and how does it apply to physiotherapists?', which provides an overview of the epidemiology and classification of axial SpA, and highlights the clinical features that physiotherapists should look for to identify potential patients.

Module objectives

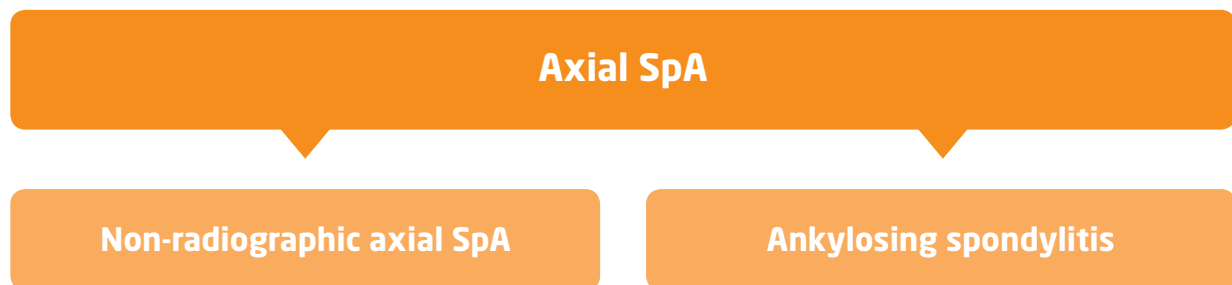By the end of this module, you should:

- Know the assessments involved in reaching a diagnosis of axial SpA.
- Understand the features of axial SpA and how these are identified.
- Be able to recognise extra-articular manifestations in a patient's history.
- Be aware of co-morbidities associated with axial SpA.
- Be confident in determining which patients may need to be referred for specialist intervention if they present with or have a history of SpA features.

*ASAS is an international group of experts who work to support and promote the study of axial SpA. More information can be found on their website: www.asas-group.org

What is axial SpA?

- Axial SpA describes a spectrum of chronic inflammatory arthritis involving the spine and/or sacroiliac joints. A predominant symptom is often chronic inflammatory back pain (IBP).¹
- Axial SpA includes non-radiographic axial SpA (nr-axSpA) and ankylosing spondylitis (AS); nr-axSpA is axial SpA without radiographic evidence of AS.¹



- In many patients, the disease follows a progressive course. However, not all patients with nr-axSpA go on to develop AS.
 - Nr-axSpA progresses to AS at a rate of about 12% over 2 years.²

Axial SpA patient characteristics

- 57% of patients with nr-axSpA are female.³
 - Unlike AS, where males are more likely to be affected (~65%).³
- Most patients are <45 years old at symptom onset.³⁻⁷
- Axial SpA affects both men and women in their most productive years.
- Nr-axSpA patients have a similar burden of disease to patients with AS.^{3,4}
- Predominant symptom is IBP.¹

More detail on axial SpA is available in Module 2 of this series (please refer to the back of this document for details on how to obtain a copy)

The ASAS features of axial SpA

Identifying axial SpA can be challenging due to the various ways in which the condition may manifest. The ASAS classification criteria define specific clinical features that may be used in combination with laboratory or imaging findings to diagnose axial SpA.⁸ Therefore, if your patient presents with unresolved chronic lower back pain or IBP, it may be worth you questioning your patient as to whether they have any of the features below, in order to support a diagnosis of axial SpA.

The diagram below shows the features of axial SpA as specified in the ASAS classification criteria.⁸

In patients with chronic back pain (≥3 months) who were <45 years old at onset⁸

**Sacroiliitis on imaging*
plus
≥1 SpA feature
(listed below)**

**HLA-B27
plus
≥2 other SpA features
(listed below)**

SpA features[†]

- IBP
- Arthritis
- Heel enthesitis
- Uveitis
- Dactylitis
- Psoriasis
- Crohn's disease/ulcerative colitis
- Good response to non-steroidal anti-inflammatory drugs (NSAIDs)
- Family history of SpA
- HLA-B27 positivity
- Elevated C-reactive protein (CRP)

The ASAS criteria are a useful tool to help identify patients who might have axial SpA

The features listed above are described in more detail in the next section of this module.

^{*}Active (acute) inflammation on MRI highly suggestive of sacroiliitis associated with SpA or definite radiographic sacroiliitis according to mNYC

[†] More information on the clinical and extra-articular features of axial SpA can be found later in this module

Clinical features of axial SpA

Inflammatory back pain

IBP is a key symptom of axial SpA. Approximately 89% of axial SpA patients are classified as having IBP.⁸

A diagnosis of IBP requires the presence of 4 out of 5 of the following parameters:⁶

Age at onset
<40 years*

Insidious onset

Improvement
with exercise

No improvement
with rest

Pain at night
(with improvement
upon getting up)

If you suspect IBP, it is important to refer the patient to a rheumatologist for further investigation

Arthritis

- Arthritis suggestive of SpA typically affects the lower limbs, with asymmetrical involvement and may involve one or several joints.⁹
- Proximal joints (i.e., hip and shoulder) are frequently involved, although any joint may be affected.
- According to the ASAS classification criteria for axial SpA, past or present active synovitis must be diagnosed by a physician.⁸

Good response to NSAIDs

- Patients with axial SpA usually have a good response to NSAIDs.
- The ASAS criteria define a 'good response to NSAIDs' as the back pain not being present any more or being significantly improved 24-48 hours after a full dose of a NSAID.⁸

Family history of SpA

- Axial SpA has a strong genetic link (see page 12 for more information).
- The ASAS criteria define a family history of SpA as the presence in first-degree (mother, father, sisters, brothers, children) or second-degree (maternal and paternal grandparents, aunts, uncles, nieces and nephews) relatives of any of the following:⁸
 - AS
 - Psoriasis
 - Acute uveitis
 - Reactive arthritis
 - Inflammatory bowel disease (IBD)

More detail on IBP is available in Modules 1 and 2 of this series (please refer to the back of this document for details on how to obtain copies).

* Age of back pain onset <40 years according to IBP criteria. Age of onset <45 years of age to meet ASAS criteria for axial SpA.

Extra-articular manifestations

Axial SpA primarily affects the spine; the sacroiliac joints in particular. However, there are additional characteristics that can occur outside of the joints; these are known as extra-articular features or manifestations. The main extra-articular manifestations associated with axial SpA are:¹

- Arthritis
- Anterior uveitis
- IBD
- Psoriasis
- Dactylitis
- Enthesitis

If you suspect a patient has axial SpA, you should assess for the presence of any extra-articular manifestations and be vigilant when taking the patient's history.

Patients who present with back pain and a history of any of the extra-articular manifestations of axial SpA (either in themselves or family members) should raise the suspicion of axial SpA. You should initiate a referral to a rheumatologist via your local referral pathway

1. Anterior uveitis

- Anterior uveitis is the most common form of uveitis - an inflammation of the uvea, the middle layer of the eye.¹⁰
- Anterior uveitis is the most common extra-articular manifestation associated with axial SpA and may precede the onset of IBP.¹⁰
 - Patients with AS have a 20-30% chance of developing uveitis during the course of their disease.
- Typically, only one eye is affected and symptoms include redness, pain and photophobia.¹¹

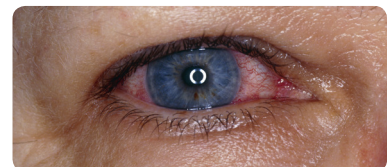
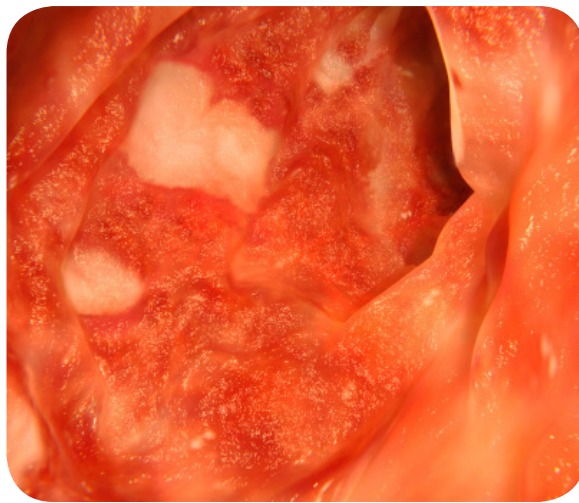


Image courtesy of
Dr H.C.Robinson/Science Photo Library

2. IBD

- IBD may be present as either Crohn's disease or ulcerative colitis.
- IBD is present in 5-10% of patients with AS.
- A history of self-diagnosed IBD or persistent diarrhoea (for which they have not sought medical advice) may still be indicative of axial SpA.

Ulcerative colitis



Symptoms of Crohn's disease and ulcerative colitis

Crohn's disease

- Abdominal pain
- Weight loss
- Diarrhoea
- Fever

Ulcerative colitis

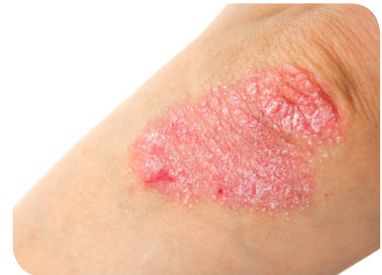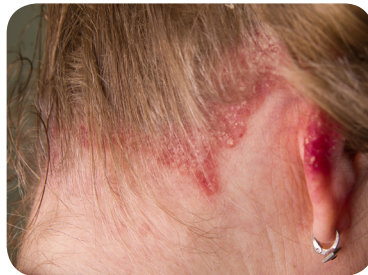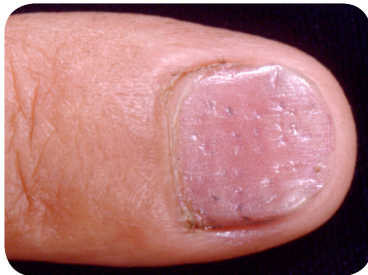- Bloody diarrhoea
- Colicky abdominal pain
- Urgency of bowel movements

3. Psoriasis

- Psoriasis is an acute, intermittent or chronic skin disease characterised by red scaly plaques.
- Plaques may be present on any area of the body, including the scalp and nails.
- Psoriasis is present in approximately 9% of patients with AS.

Psoriasis

Psoriasis may appear on any area of the body. Typical manifestations include moderate-to-severe nail changes and scaly patches and plaques



Nail pitting image courtesy of Dr Karl Gaffney

4. Dactylitis

- Dactylitis is the swelling of fingers and/or toes which may or may not be painful.
- Dactylitic fingers or toes are often described as 'sausage-digits'.
- Dactylitis is present in approximately 5-6% of patients with axial SpA.
- It should be noted that dactylitis is distinctly different to synovial joint swelling.
- In finger dactylitis, swelling may be so pronounced that the patient may not be able to flex their finger.

Dactylitis

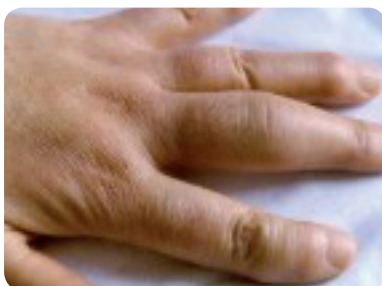

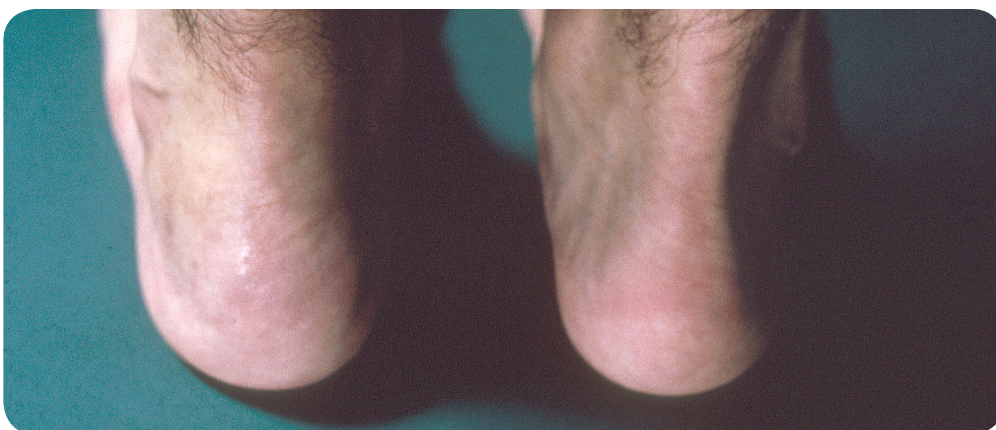Image courtesy of Susan Gurden

Dactylitis occurring in the middle
finger of the left hand

5. Enthesitis

- Enthesitis is inflammation - with or without pain - of the sites of insertion of tendon, ligament, fascia or joint capsule to bone.
- Approximately 14% of patients with AS and 20% of patients with non-radiographic axial SpA are affected by enthesitis.
- Heel enthesitis - past or present - is required to meet the ASAS definition of enthesitis as a feature of axial SpA.⁸
 - However, enthesitis may be present at any enthesis site over the body; the lower limbs (typically bone but also anterior knee) are more frequently involved than those of the upper extremities.
- Enthesitis may involve the synovial joints, fibrocartilaginous joint, syndesmoses and extra-articular entheses.
- Chest wall enthesitis may be present in approximately a quarter of patients with axial SpA.¹⁴
- Enthesitis may be difficult to recognise as the features are similar to mechanical diseases such as tendinopathy (impaired tendon healing characterised by pain, swelling, and impaired performance).^{15,16}
 - Palpation skills may be able to determine the position of tenderness or swelling (i.e. mid tendon in tendinopathy or adjacent to bone in inflammatory enthesitis).

Enthesitis



© 2015 American College of Rheumatology. Used with permission.

Enthesitis of the left heel

Two different sites at the heel can be affected:

- The insertion of Achilles tendon on the posterior part of calcaneum. This is responsible for posterior heel pain.
- The insertion of plantar fascia on the inferior part of calcaneum. This is responsible for inferior heel pain.

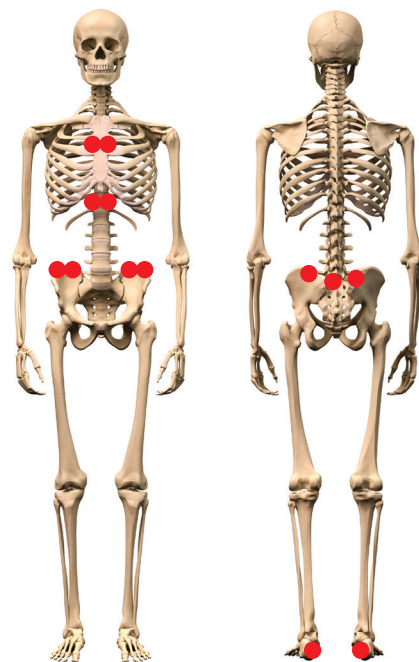
The Maastricht Ankylosing Spondylitis Enthesitis Score (MASES) is an index (range 0-13) for assessing enthesitis in patients with axial SpA.¹⁷ You may wish to consider assessing the areas highlighted below to determine if the patient has any tenderness.

For further information on enthesitis, the review paper *Entheses, Enthesitis and Enthesiopathy* (McGonagle 2009) is recommended.¹⁵

The MASES¹⁷

The 13 sites of enthesitis included in the MASES:

- 1st Costochondral joint left/right
- 7th Costochondral joint left/right
- Posterior superior iliac spine left/right
- Anterior superior iliac spine left/right
- Iliac crest left/right
- 5th Lumbar spinous process
- Proximal insertion of Achilles tendon left/right.



Laboratory features of axial SpA

In suspected cases of axial SpA, the laboratory investigations below may be carried out. Although not all physiotherapists have access to blood tests, if you suspect axial SpA in a patient whose clinical features do not fully match the ASAS criteria, you may wish to liaise with your spinal pathway colleagues to suggest tests to achieve a differential diagnosis in accordance with local protocols.

HLA-B27

Axial SpA has a genetic link. The presence of the gene human leukocyte antigen B27 (HLA-B27) is a strong predictor for axial SpA.⁸

- Approximately 80-95% of patients with AS,^{3,18} and 46-75% of nr-axSpA patients are HLA-B27 positive.¹⁸
 - Patients who **do not have HLA-B27** are said to be HLA-B27 negative but **could still have axial SpA**.
- **HLA-B27 positivity** has been shown to be **associated** with an **earlier onset** of disease and the presence of uveitis.¹⁸
- Approximately 8-9% of the UK population is HLA-B27 positive,¹⁹ but only approximately 5% of HLA-B27 carriers will develop a form of spondyloarthritis.²⁰

C-reactive protein

- C-reactive protein (CRP) is a protein present in blood, the **levels of which rise in response to inflammation**. Elevated levels of CRP may be associated with structural changes in the spine associated with axial SpA.³
- Once other potential causes for elevated CRP have been ruled out, a CRP concentration above the upper limit of normal (ULN), in the presence of back pain, is considered a feature of axial SpA.⁸
- **Patients without elevated CRP may still have axial SpA.** Approximately 48% of AS patients and 70% of nr-axSpA patients have normal levels of CRP (<6 mg/litre).³

ESR

- Erythrocyte sedimentation rate (ESR) is **another measure of inflammation**, commonly used in the assessment of RA (rheumatoid arthritis) and other inflammatory disorders. **ESR is not an ASAS axial SpA feature**, but may be tested because of the limited repertoire of biomarkers for axial SpA.^{21,22}

Imaging

If axial SpA is suspected, a clinician will use imaging to further investigate the presence of sacroiliitis (inflammation of the sacroiliac joint). Although not all physiotherapists have access to imaging for patients with suspected axial SpA, some may wish to liaise with their spinal pathway colleagues to suggest tests to achieve a differential diagnosis in accordance with local protocols.

Sacroiliitis

Sacroiliitis is a feature of the spondyloarthropathies, including axial SpA, and may be identified using magnetic resonance imaging (MRI) or X-ray.

MRI sacroiliitis

Unlike advanced forms of axial SpA where structural changes are visible on X-ray, nr-axSpA is characterised by active inflammation, before structural changes have taken place, which can only be seen using MRI.

- MRI is capable of detecting inflammation long before damage becomes visible on an X-ray.⁸
- However, 24% of patients with active axial SpA have no MRI-active sacroiliitis, although lesions may be visible on the spine.²³

MRI sequences used for detecting sacroiliitis

There are **different types** of MRI, each with different uses. For visualising axial SpA, the most useful MRIs to request are:²⁴

- **Short-tau inversion recovery (STIR) MRI:** this scan mode is also well suited to detecting oedema and is usually sufficient for detecting active inflammatory lesions.
- **T1-weighted MRI:** these scans offer good anatomical detail and are usually applied to evaluate structural changes.

X-ray (radiographic) sacroiliitis

Not all patients who have axial SpA will exhibit radiographic features.^{8,25}

- X-rays can only detect chronic bony damage which is the consequence of inflammation over a significant period of time, rather than inflammation itself. Patients with visible changes on X-ray are described as having AS, a more advanced form of axial SpA.

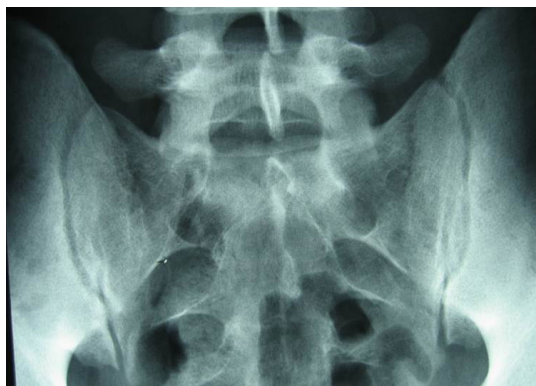X-ray can be used to identify structural changes but cannot detect inflammation itself.

Defining radiographic sacroiliitis

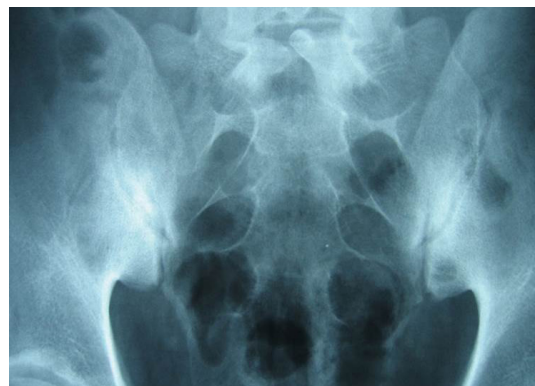Radiographic sacroiliitis is defined as bilateral grade 2–4 or unilateral grade 3–4, as per the modified New York Criteria (mNYC).²⁵ Further information on the mNYC can be found in the appendix.

MRI is the most useful imaging tool for detecting sacroiliitis, but X-ray can also be used to detect later forms of axial SpA

The radiographic grades of sacroiliitis:²⁵

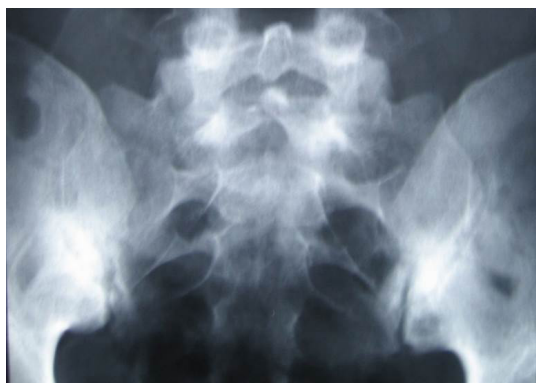

Grade 0: Normal.

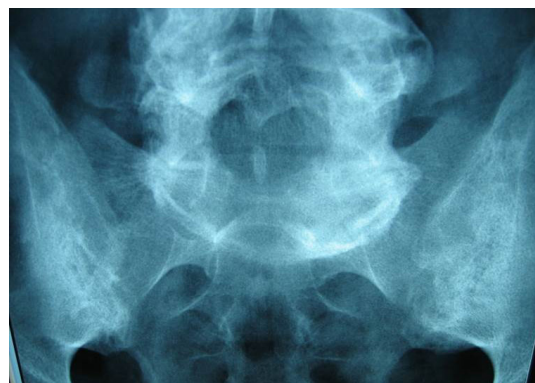

Grade 1: (not shown) Suspicious (no specific abnormality).

Grade 2: Minimum abnormality (loss of definition at the edge of the sacroiliac joints, there is some sclerosis and perhaps minimal erosion, there may be some joint space narrowing).



Grade 3: Moderate abnormality (definite sclerosis on both sides, blurring and indistinct margins and erosive changes with loss of joint space).

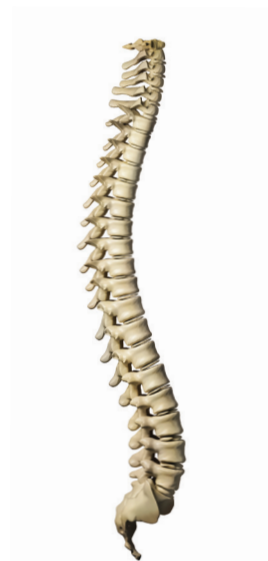

Grade 4: Complete ankylosis (without residual sclerosis).

Images courtesy of Dr Alexander Bennett

Whole spine imaging

- It is important to remember that while disease often starts in the sacroiliac joint, inflammation may be present in any part of the spine.
- In nr-axSpA active inflammation may be detected using MRI at both the spine and sacroiliac joints^{23,26} and whole spine MRI is considered an important and useful examination by many rheumatologists.
 - However, active inflammation of the spine is not included in the ASAS classification criteria.



Recommendations for radiologists

Which MRI scans to request?

Radiologists receiving a request for an inflammatory back pain MRI should perform:²⁷

1. STIR and T1 weighted sequences of the whole spine (sagittal view)
2. STIR and T1 weighted sequences of the sacroiliac joints (coronal oblique view)

ASAS/OMERACT guidelines for SIJ MRI interpretation²⁸

- Bone marrow oedema representing an inflammatory lesion that meets the criterion for a positive sacroiliac joint will usually be easily seen on at least two consecutive slices of an MRI scan
- Detection of inflammation on a single slice may be sufficient for the criterion 'highly suggestive of SpA' if there is more than one inflammatory lesion present

For full guidelines on the definition of a positive sacroiliac joint MRI, please refer to full publication.²⁸

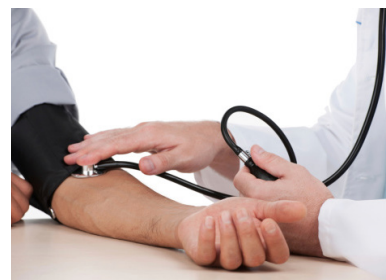Although whole spine MRI or X-ray may be useful, pelvic MRI or X-ray should always be requested

Axial SpA co-morbidities

Axial SpA is associated with other co-morbidities that need to be considered when assessing and treating patients. However, it should be noted that these do not form part of the diagnosis of axial SpA for a patient.

Cardiovascular involvement

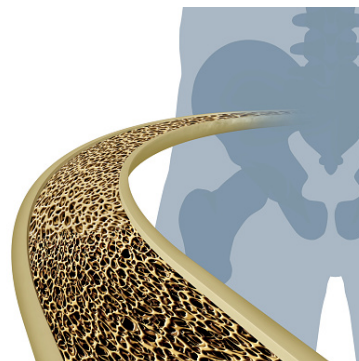
- Patients with axial SpA are at an increased risk of cardiovascular events than the general population.²⁹
- Cardiovascular manifestations may occur in 2-10% of patients with AS³⁰ and the risk of cardiovascular events is increased 30-50% compared to the general population.³¹
- Cardiovascular risk management is needed in patients with AS. EULAR recommends a risk assessment at least once every 5 years and following major changes in antirheumatic therapy.³²



Lifestyle recommendations to all patients should emphasise the benefits of a healthy diet, regular exercise and smoking cessation.³²

Osteoporosis

- Bone loss leading to osteoporosis is a feature of inflammatory disorders including AS.³³
- Osteoporosis may be present in up to 47% of patients with AS.^{34,35}
- Patients should be aware of their increased risk of fractures. Of note, pre-existing back pain can mask and delay the diagnosis of spinal fractures.³³
- Physiotherapists and other members of the multi-disciplinary team can help to prevent fractures through assessment of bone strength and appropriate exercises.



More detail on appropriate exercises is available in Module 4 of this series (please refer to the back of this document for details on how to obtain a copy).

It is important that patients with axial SpA are aware of the associated cardiovascular and fracture risks and are provided with support and education in order to make appropriate lifestyle changes

Pulmonary function

Up to half of patients with AS may have impaired pulmonary function.³⁶⁻³⁸

- In patients with AS impaired pulmonary function is associated with reduced spinal flexibility³⁸ and can impact on patients' quality of life.³⁶
- Physiotherapy and exercise are important to maintain spinal flexibility in patients with axial SpA.³⁹
- Patients with severely impaired spinal mobility should be referred to a specialist for thorough examination including pulmonary function tests (spirometry) and treatment.³⁸

Physiotherapy for patients with axial SpA should include exercises to improve or maintain:

Cardiovascular fitness

Bone strength

Spinal flexibility

Assess your knowledge of the clinical features of axial SpA

Please complete the multiple choice questions below.

1. Which of the following statements are true? (tick all that apply)
 - a. All axial SpA patients will be positive for HLA-B27 ☐
 - b. A patient may be classified as having axial SpA if they are HLA-B27 positive and have sacroiliitis visible through MRI ☐
 - c. HLA-B27 has been shown to be associated with an earlier onset of axial SpA ☐
 - d. HLA-B27 positivity in axial SpA patients is associated with a reduced risk of dactylitis ☐
2. Which of the following MRI sequences are recommended for patients with axial SpA? (choose one answer)
 - a. STIR and T1 ☐
 - b. T1 and T2 ☐
 - c. STIR only ☐
 - d. T1 only ☐
3. Which of the following cannot be visualised on X-ray? (tick all that apply)
 - a. Sclerosis ☐
 - b. Erosion ☐
 - c. Ankylosis ☐
 - d. Active inflammation ☐
4. Which of the following is not a feature of axial SpA according to the ASAS criteria for the classification of axial SpA? (tick all that apply)
 - a. Dactylitis ☐
 - b. Elevated CRP ☐
 - c. Good response to DMARDs ☐
 - d. Mechanical back pain ☐
5. Which of the following is not recognised as an extra-articular manifestation of axial SpA?(choose one answer)
 - a. Crohn's disease ☐
 - b. Psoriasis ☐
 - c. Septic arthritis ☐
 - d. Ulcerative colitis ☐

6. Approximately what proportion of AS patients have Crohn's disease or ulcerative colitis at diagnosis?(choose one answer)
 - a. 1.4% ☐
 - b. 4% ☐
 - c. 14% ☐
 - d. 40% ☐

7. Which of the following is a feature of dactylitis? (tick all that apply)
 - a. Painless swelling of toes ☐
 - b. Painless swelling of fingers ☐
 - c. Swelling of toes with pain ☐
 - d. Swelling of fingers with pain ☐

8. Which of the following may be a feature of axial SpA according to the ASAS criteria? (choose one answer)
 - a. Enthesitis of the patella ☐
 - b. Enthesitis of the heel ☐
 - c. Enthesitis of the ischial bones ☐
 - d. Enthesitis of the shoulder ☐

9. According to the ASAS classification criteria for axial SpA, a good response to NSAIDs is defined as the pain improving how long after a full dose? (choose one answer)
 - a. 2-4 hours ☐
 - b. 12-14 hours ☐
 - c. 24-48 hours ☐
 - d. Up to a week ☐

10. Which of the following would be considered a feature of axial SpA? (tick all that apply)
 - a. Mother with SpA ☐
 - b. Grandmother with SpA ☐
 - c. Mother-in-law with axial SpA ☐
 - d. Son with SpA ☐

Answers are provided on the back page

Personal reflection and new key learning points

Personal actions

1. What will I do differently in daily clinical practice?

2. What key questions will I ask my patients with chronic lower back pain?

3. What further training or information do my team and I need?

Glossary

Axial spondyloarthritis (SpA)

A form of spondyloarthritis, composed of both non-radiographic axial SpA (nr-axSpA) and ankylosing spondylitis (AS), and where radiographic sacroiliitis may or may not be present.

Crohn's disease

A chronic inflammatory disease of the intestines, especially the colon and ileum, associated with ulcers and fistulae.

Dactylitis

An inflammation of the fingers and/or toes with or without pain. Dactylitic fingers and toes are often referred to as 'sausage digits'.

Enthesitis

Inflammation of the entheses, the points at which a tendon or ligament or muscle inserts onto bone.

Human Leukocyte Antigen (HLA)-B27

A class I surface antigen encoded by the B complex in the major histocompatibility complex on chromosome 6. HLA-B27 positivity is associated with spondyloarthritis.

Modified New York Criteria (mNYC)

A set of radiographic and clinical criteria used for the diagnosis of AS.²² Please see the appendix for full details.

Psoriasis

A chronic, inflammatory disease characterised by scaly skin lesions, which can be in the form of patches, papules, or plaques.

Sacroiliitis

Originally used to describe bony changes in the sacroiliac joint on plain X-ray, the term is also used to describe inflammation of the sacroiliac joint seen on MRI.

Syndemophytes

Bony growths originating inside a ligament, commonly seen in the ligaments of the spine.

Ulcerative colitis

An inflammatory bowel disease characterized by inflammation with ulcer formation in the lining of colon (large intestine).

Uveitis

Inflammation of the uvea, the middle layer of the eye. The most common type of uveitis is an inflammation of the iris called anterior uveitis (iritis).

Appendix

Modified New York Criteria (mNYC) for the diagnosis of AS²⁵

A diagnosis of definite AS may be made if the radiological criterion is present plus at least one clinical criterion.

Radiologic criteria:

- Sacroiliitis grade ≥ 2 bilaterally or sacroiliitis grade 3-4 unilaterally.

Clinical criteria:

- Low back pain and stiffness for >3 months.
- Limitation of motion of the lumbar spine in both the sagittal and frontal planes.
- Limitation of chest expansion relative to normal values corrected for age and sex.

Useful contacts and further information

British Health Professionals in Rheumatology (BHPR)

www.rheumatology.org.uk

NASS guide to inflammatory back pain

<https://nass.co.uk/about-as/getting-my-diagnosis>

The Chartered Society of Physiotherapy (CSP)

www.csp.org.uk

AStretch

www.astretch.co.uk

ASAS

www.asas-group.org

Modules in this series

Module 1: Differentiating Inflammatory and Mechanical Back Pain

A comparison of the features of inflammatory and mechanical back pain and a detailed outline of the assessment and diagnosis process for inflammatory back pain.

Module 2: What is Axial Spondyloarthritis?

An overview of the epidemiology, symptoms and classification of axSpA, and the clinical features that identify potential patients.

Module 3: Assessing the Signs, Symptoms and Clinical Manifestations of Axial SpA

Information on the key clinical features and extra-articular manifestations of non-radiographic axial SpA and AS and how to identify these.

Module 4: Treatment of Axial Spondyloarthritis

Non-pharmacological and pharmacological management of patients with axSpA.

References

1. Rudwaleit M, et al. *Ann Rheum Dis*. 2009;68:770-6; **2**. Poddubnyy D, et al. *Curr Opin Rheumatol*. 2012;24:363-9; **3**. Rudwaleit M, et al. *Arthritis Rheum*. 2009;60:717-27. **4**. Kiltz U, et al. *Arthritis Care & Res*. 2012;64:1415-22; **5**. van der Heijde D, et al. *Arthritis Rheum*. 2006;54:2136-46; **6**. Sieper J, et al. *Ann Rheum Dis*. 2009;68(Suppl II):ii1-ii44; **7**. Haibel H, et al. *Arthritis Rheum*. 2008;58:1981-91; **8**. Rudwaleit M, et al. *Ann Rheum Dis*. 2009;68:777-83; **9**. Dougados M, et al. *Arthritis Rheum*. 1991;34:1218-27; **10**. Chang JH, et al. *Survey Curr Ophthalmol*. 2005;50:364-88; **11**. El Maghraoui A. *Eur J Intern Med*. 2011;22(6):554-60; **12**. Stolwijk C, et al. *Ann Rheum Dis*. 2015;74:65-73; **13**. de Winter JJ, et al. *Arthritis Res Ther*. 2016;18:196; **14**. Weber U, et al. *Arthritis Res Ther*. 2012;14(1):R3; **15**. McGonagle D and Benjamin M. *Topical Reviews*. 2009;6(4):1-6; **16**. BMJ Best Practice - Tendinopathy. Available at: <http://bestpractice.bmj.com/best-practice/monograph/582.html>. Accessed: September 2017. **17**. Heuft-Dorenbosch L, et al. *Ann Rheum Dis*. 2003;62:127-132; **18**. Chung HY, et al. *Ann Rheum Dis*. 2011;70:1930-1936; **19**. Orchard TR, et al. *Aliment Pharmacol Ther*. 2008;29:193-7; **20**. Colbert RA, et al. *Prion*. 2009;3:15-326; **21**. Taylor HG, et al. *Br J Rheumatol*. 1991;30:330-5; **22**. Sieper J, et al. *Ann Rheum Dis*. 2002;61:iii8-iii18. **23**. Bennett A, et al. *Arthritis Rheum*. 2009;60:1331-1341; **24**. Ostergaard M and Lambert RGW. *Ther Adv Musculoskel Dis*. 2012;4:301-311; **25**. van der Linden S, et al. *Arthritis Rheum*. 1984; 27:361-8; **26**. Rudwaleit M, et al. *Ann Rheum Dis*. 2008; 67:1276-1281; **27**. NICE [2017] Spondyloarthritis in over 16s: diagnosis and management. Available from <https://www.nice.org.uk/guidance/ng65>. All rights reserved. Subject to Notice of rights. NICE guidance is prepared for the National Health Service in England. All NICE guidance is subject to regular review and may be updated or withdrawn. NICE accepts no responsibility for the use of its content in this product/publication; **28**. Lambert RG, et al. *Ann Rheum Dis*. 2016;75(11):1958-63; **29**. Sveaas SH, et al. *PLoS One*. 2014;30(9):e108688; **30**. Ozkan Y. *J Clin Med Res*. 2016;8(6):427-30; **31**. Eriksson JK, et al. *Ann Rheum Dis*. 2016;0:1-7. doi:10.1136/annrheumdis-2016-209315; **32**. Agca R, et al. *Ann Rheum Dis*. 2017;76(1):17-2833; **33**. Briot K and Roux C. *RMD Open*. 2015;1:e000052; **34**. Klingberg E, et al. *Arthritis Res Ther*. 2012;14:R108; **35**. Kilic E and Ozgocmen S. *World J Orthop*. 2015;6(2):298-310; **36**. Dincer U, et al. *Tohoku J Exp Med*. 2007;212:423-430; **37**. Sampaio-Barros PD, et al. *Clin Rheumatol*. 2007;26:225-230. **38**. Berdal G, et al. *Arthritis Res Ther*. 2012;14:R19; **39**. Millner JR, et al. *Semin Arthritis Rheum*. 2016;45:411-27.

Answers to questions

1:b,c; **2:**a; **3:**d; **4:**c,d; **5:**c; **6:**b; **7:**a,b,c,d; **8:**b; **9:**c; **10:**a,b,d.